

Ultrastructural Alterations in the Epidermis of Patients with Tinea Pedis

Y. Canberk¹, D. Kocabalkan Selcuki², B. Ahishali¹, F. Durmaz Onar¹, and E. Karabulut¹

1. Department of Histology and Embryology, Istanbul Faculty of Medicine, Istanbul University, 34390 Capa Istanbul, Turkey.

2. Department of Dermatology, Istanbul Faculty of Medicine, Istanbul University, 34390 Capa Istanbul, Turkey.

ycanberk@istanbul.edu.tr

Keywords: skin, tinea pedis, transmission electron microscopy

Tinea pedis (athlete's foot) is the most common superficial fungal infection of the foot [1-3]. Although light microscopic characteristics of the lesions of tinea pedis are already described and well known, electron microscopic data is still lacking. Therefore, this study was conducted to outline ultrastructural features of epidermis in patients with tinea pedis.

For this purpose biopsies of the lesions between the toes of 10 male patients with untreated tinea pedis and 3 healthy volunteers with no fungus infections were examined by electron microscopy.

When compared to normal skin, various degenerative changes were found in all epidermal layers of patients with tinea pedis. The most affected layer was the stratum spinosum which lacked the regular cellular organization (Fig.1). Tonofilament bundles were of varying thickness and length and irregularly distributed along the cytoplasm. Besides significant expansion in intercellular spaces, keratinocytes of varying shapes were observed to lose their intercellular junctions owing to disrupted desmosomes (Figs.1, 2 and 3). Lymphocytes and polymorphonuclear leucocytes were noticed between the keratinocytes (Fig.1). Significant degenerative ultrastructural changes were seen in the stratum basale. Tonofilaments were arranged in small bundles and irregularly dispersed in the cytoplasm of basal cells. Round granules with comparable ultrastructure to those observed in keratinocytes of stratum spinosum were noticed in the cytoplasm basal cells (Fig. 2). Expansions between the collagen fibers of connective tissue probably representing edematous areas and accumulation of a homogenous material were remarkable (Fig.3). Melanocytes showing moderate number of melanosomes were found among basal cells in the stratum basale (Fig. 4).

These results provide ultrastructural evidences to describe for the first time electron microscopic features of epidermis in patients with tinea pedis.

1. Das S, Goyal R, Bhattacharya SN. Laboratory-based epidemiological study of superficial fungal infections. *J Dermatol* (2007); 34:248-253.
2. Wu H, Schapiro B, Harrist TJ. Noninfectious vesiculobullous and vesiculopustular diseases. In: Elder DE, Elenitsas R, Johnson BL, Murphy GF, eds. *Lever's Histopathology of the skin*. 9th ed. Philadelphia, JB Lippincott; (2005): 244-246.
3. Al Hasan M, Fitzgerald SM, Saoudian M, Krishnaswamy G. Dermatology for the practicing allergist: Tinea pedis and its complications. *Clin Mol Allergy* (2004); 2:5.

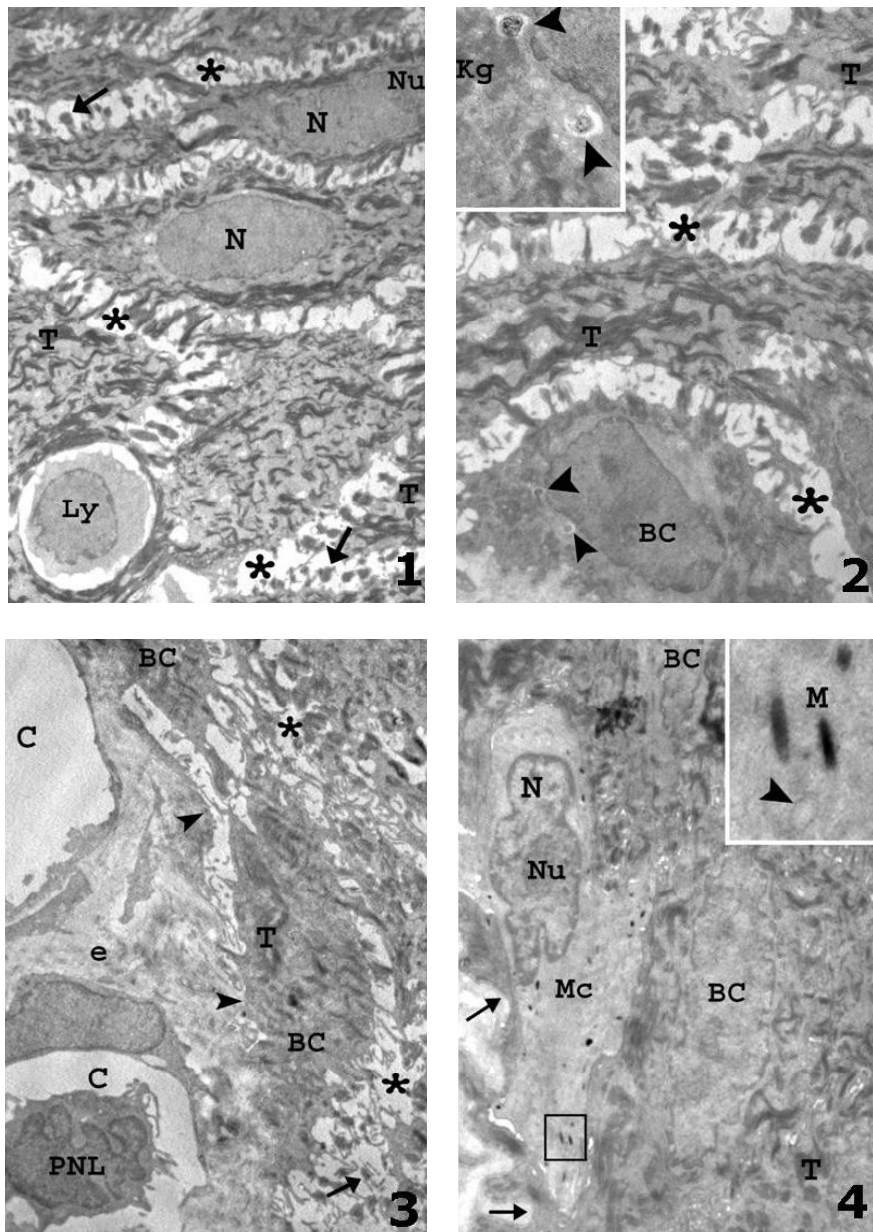


Figure 1. Stratum spinosum from a patient with tinea pedis. Note the widened intercellular spaces (asterisks) and disrupted desmosomes (arrows) between adjacent keratinocytes. N: nucleus, T: tonofilament bundles, Ly: lymphocyte (X 5,000).

Figure 2. Stratum basale and papillary dermis from a tinea pedis lesion. Basal cells (BC) show deterioration of cellular attachments with disrupted desmosomes (arrow) and papillary dermis exhibits pericapillary edema (e). Arrowhead: gaps in basal lamina, PNL: leucocyte, C: capillaries (X 7,500).

Figure 3. Epidermal basal layer of a tinea pedis lesion. BC: basal cell. Inset shows a portion of a basal cell containing round granules containing granular cores and electron-lucent mantle (arrowheads) and keratohyalin granules (Kg) (X 7,500; inset X 25,000).

Figure 4. A melanocyte (Mc) from stratum basale of a tinea pedis lesion showing moderate number of melanosomes. Nu: nucleolus, arrows: diminished interdigitations in epidermodermal junction. Inset shows higher magnification of the area in the square with melanosomes (M) and mitochondria (arrowhead) (X 7,500; inset X 25,000).