

## Immunohistochemical localization of necl-5 in melanocytic skin lesions. Preliminary observations

F. D'Amico, A. Amoroso, E. Skarmoutsou, M. Consolo, Y. Bevelacqua, F. Stivala, M.C. Mazzarino, and G. Malaponte

Department of Biomedical Sciences, University of Catania, 95124 Catania, Italy

f.damico@unict.it

Keywords: Necl-5, CD155, PVR, immunohistochemistry, skin

Nectin like-5 (necl-5) protein, also termed as PVR/CD155/Tag4, is a member of the immunoglobulin superfamily. There are five known members of the necl family. Necl-5 is a highly glycosylated transmembrane cell surface protein with three extracellular domains, a transmembrane region and a cytoplasmic tail [1]. Necl-5 is ubiquitously expressed in many tissues, such as brain, kidney, liver, lung, leukocytes, and plays important roles in cell-cell adhesion during normal and pathological processes, in cell migration and proliferation [2]. Moreover, Necl-5 expression is often upregulated in cancer, but its physiological significance in the development of cancer remains unclear [3].

In an effort to gain additional information on the localization of necl-5 molecule on normal and pathological skin, we have examined the immunohistochemical expression of necl-5 in archival tissue sections from normal, with melanocytic nevus, and melanoma tissues. Furthermore, flow cytometry analysis on primary epidermal melanocytes (ATCC number PCS-200-012) and on M14 melanoma cell line were performed to assess membrane expression of Necl-5.

Five-micrometre-thick sections from paraffin-embedded tissue blocks were placed on silanized slides. After deparaffinization, rehydration and treatment with 0.3% hydrogen peroxide, sections were incubated with diluted normal blocking serum for 20 min at room temperature. Subsequently, the sections were incubated with rabbit polyclonal primary antibody anti-PVR, diluted 1:150 (ab60115, Abcam, UK), for 1 h at room temperature. The immunodetection was carried out using Histostain-Plus Kit (Zymed, USA) according to the manufacturer's instructions. AEC (3-amino-9-ethylcarbazole) was used as a chromogen. Negative control experiments were performed substituting the primary antibody with non immune serum and by omitting the primary antibody, thus incubating slides only with buffer. Immunolabelled and random systematically sampled sections were observed using a Leica DMRB microscope (Leica, Germany) and photographed with a Canon G-9 camera (Canon, Japan). Random systematically sampled sections were analyzed using ImageJ software (version 1.42g) [4]. Staining intensity was analysed with the color deconvolution plugin [5]. For semiquantitative immunohistochemical analysis, statistical comparisons of area densities were performed using one-way ANOVA.

For cytometry analysis 50  $\mu$ l of cells in a concentration of  $1 \times 10^6$ /ml in generic culture medium were stained with 10  $\mu$ l of phycoerythrin conjugated mouse IgG1 isotype control and mouse IgG1 anti-human CD155 (PVR) (eBioscience, USA). Cells were analyzed using a FACScalibur flow cytometer (Becton Dickinson, USA). After gating cells on a forward scatter/side scatter dot plot window on linear scale, the fluorescence intensity of PE-conjugated isotype control and anti-CD155 labelled cells were analyzed in histograms on FL2 channel with logarithmic scales. Histograms were then compared in an overlay window.

Our results showed that normal skin expressed a discrete amount of necl-5 protein (fig. a), which was mainly localized on the membranes of the prickle cell layer. The skin of nevus

showed similar immunolabelling patterns, however a strong labelling was mainly found on the prickle layer (fig. b). The dermis of the above types of tissues was discretely labelled. Melanoma tissue showed the above characteristic pattern, however a semiquantitative analysis showed a significant increase in comparison to the other types of examined tissues. Moreover, the dermis of melanoma tissue was strongly immunostained (fig. c).

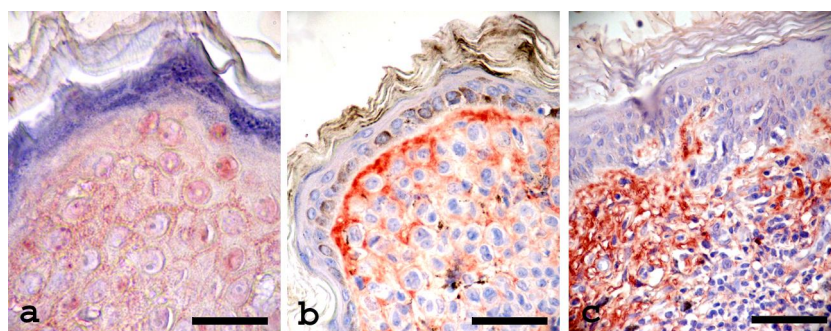
Flow cytometric analysis revealed an increased expression of the marker on tumour cells compared to normal melanocytes.

Such preliminary observations suggest that necl-5 is upregulated in melanoma tissues, playing an important role in cell proliferation and in promoting metastasis.

It is known that necl-5 shows alternative functions, such as the interaction with natural killer cell (NK) activating DNAM-1 receptor [6]. Stimulation of NK cells by the overexpressed necl-5 could play important role in the tumour development. Further investigation is necessary to define the mechanisms of the upregulation of necl-5 during skin diseases.

Although such data are preliminary, our immunostaining patterns for necl-5 may contribute to the development of new strategies for diagnosis of such diseases.

1. C.L. Mendelsohn et al., *Cell* 56 (1989) p855.
2. Y. Takai et al., *Nature Rev. Mol. Cell Biol.* 9 (2008) p603.
3. K.E. Sloan et al., *BMC Cancer* 4 (2004) p73.
4. W. S. Rasband, <http://rsb.info.nih.gov/ij/> (1997-2008).
5. A. C. Ruifrok and D.A. Johnston, *Anal. Quant. Cytol. Histol.* 23 (2001) p291.
6. C. Bottino et al., *J. Exp. Med.* 198 (2003) p557.



**Figure.** Immunohistochemical localization of Necl-5 in normal (a), with nevus (b), and melanoma (c) skin tissues (bars, a: 20  $\mu$ m, b: 40  $\mu$ m, c: 45  $\mu$ m).